

Editors: Fischer, Josef E.

Title: *Fischer's Mastery of Surgery, 6th Edition*

Copyright ©2012 Lippincott Williams & Wilkins

> Table of Contents > VIII - Nongastrointestinal Transabdominal Surgery: A the Spleen > D - Surgery of Hernia > 205 - Lichtenstein Tension-Free Hernioplasty

205

Lichtenstein Tension-Free Hernioplasty

Parviz K. Amid

David C. Chen

Weakening of the abdominal wall tissue as one of the causes of inguinal hernias was suspected by Cooper as far back as 1800. The matter was emphasized again in 1922 by Harrison when he wondered why a significant number of men develop hernias at age 50 to 60, years after their active life is over. Need for prosthetic reinforcement of weakened abdominal wall tissue was recognized by Billroth, musing "If only the proper material could be created to artificially produce tissue of density and toughness of fascia and tendon, the secret of the radical cure for hernia would be discovered." However, early generations of prostheses resulted in disastrous complications from rejection and infection. It was not until the introduction of polypropylene mesh by Usher in 1959 that Billroth's dream was realized.

With the necessity of prosthesis for the repair of inguinal hernia in mind, and focusing on the principle of "no tension" (considered one of the great principles of surgery by Halstead), the Lichtenstein group popularized routine use of mesh in 1984 and coined the term "tension-free hernioplasty." During the rapid evolution of hernia surgery throughout the past decade, it was left to Nyhus to remove the previous generation's fear of infection and rejection of prosthesis, which he did when he stated in 1989, "My concerns relative to the potentially increased incidents of infection or rejection of polypropylene mesh have not been warranted to date."

Today, understanding the role of protease-antiprotease imbalance in the pathogenesis of groin hernias has led to a new grasp of the pathology of groin hernias and the causes of their surgical failure. There is morphologic and biochemical evidence that adult male inguinal hernias are associated with an altered collagen type I to type III ratio. These changes lead to weakening of the fibroconnective tissue of the groin and development of inguinal hernias. To use this already defective tissue, especially under tension, is a violation of the most basic principles of surgery.

In tension-free hernioplasty, instead of suturing anatomic structures that are not in apposition, the entire inguinal floor is reinforced by insertion of a sheet of mesh. The prosthesis that is placed between the transversalis fascia and the external oblique aponeurosis extends well beyond Hesselbach's triangle in order to provide sufficient mesh-tissue interface. On increased intra-abdominal pressure, the external oblique aponeurosis applies counterpressure to the mesh, thus using the intra-abdominal pressure in favor of the repair. The procedure addresses both issues of hazardous suture line tension and metabolic causation of inguinal hernias. The operation is therefore therapeutic as well as prophylactic; thus it repairs and protects the entire susceptible region of the groin to herniation from all future metabolic and mechanical adverse effects.

P.2110

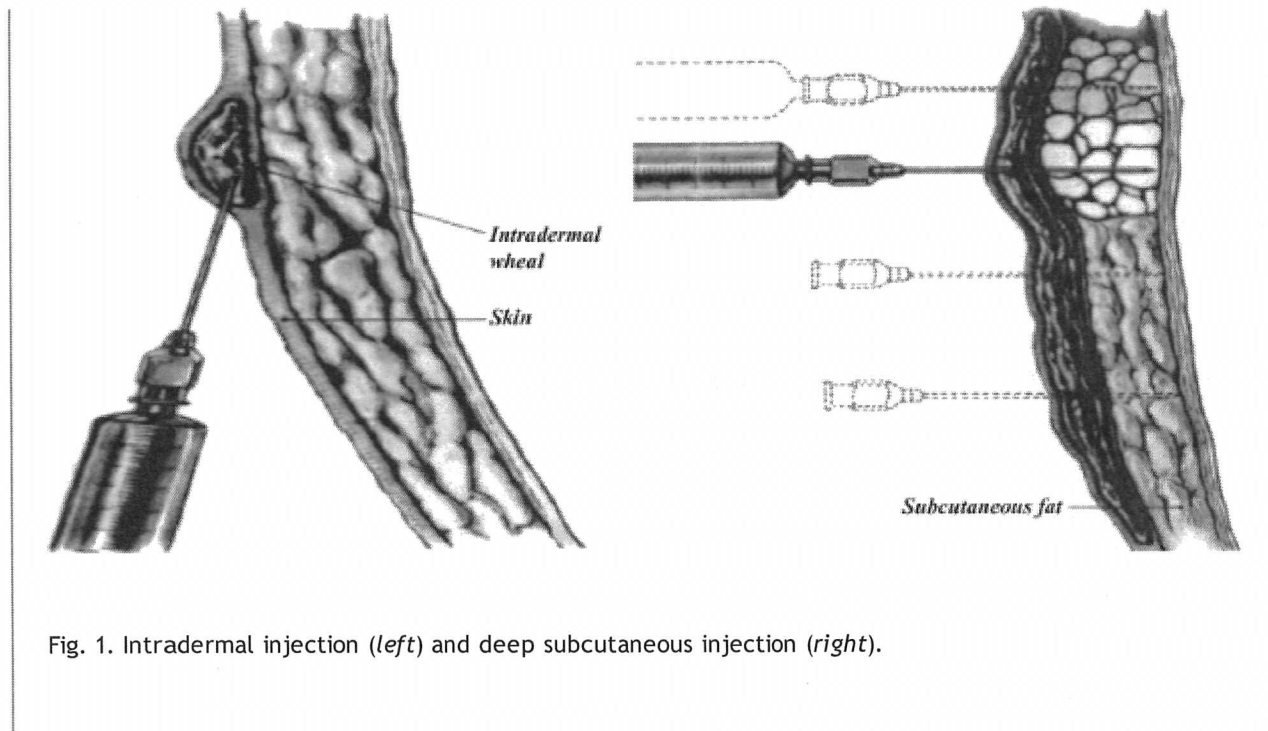


Fig. 1. Intradermal injection (*left*) and deep subcutaneous injection (*right*).

The procedure is performed under local anesthesia, which is our preferred choice for all reducible adult inguinal hernias. It is safe, simple, effective, economical, and without any side effects such as nausea, vomiting, and urinary retention. Furthermore, local anesthesia administered prior to making the incision produces a prolonged analgesic effect via inhibition of the buildup of local nociceptive molecules.

Technique of Anesthesia

Several safe and effective anesthetic agents are currently available. Our choice, however, is a 50:50 mixture of 1% lidocaine (Xylocaine) and 0.5% bupivacaine (Marcaine), with 1/200,000 epinephrine. An average of 45 mL of this mixture is usually sufficient for a unilateral hernia repair and is administered in the following fashion.

Subdermal Infiltration

Approximately 5 mL of the mixture is infiltrated along the line of the incision with a 1.5-in.-long, 25-gauge needle inserted into the subdermal tissue parallel to the surface of the skin. Infiltration continues as the needle is advanced. Movement of the needle reduces the likelihood of intravascular infusion of the drugs because even if the needle penetrates a blood vessel, the tip will not remain in the vessel long enough to deliver a substantial amount of the anesthetic agent intravenously. This step blocks the subdermal nerve endings and reduces the discomfort of the intradermal infiltration, which is the most uncomfortable stage of local anesthesia.

Intradermal Injection (Creation of the Skin Wheal)

The needle in the subdermal plane is withdrawn slowly until the tip of the needle reaches the intradermal level. Without extracting the needle completely, the dermis is infiltrated by slow injection of approximately 3 mL of the mixture along the line of the incision (Fig. 1, left).

Deep Subcutaneous Injection

A total of 10 mL of the mixture is injected deep into the subcutaneous adipose tissue through vertical insertions of the needle (perpendicular to the skin surface) 2 cm apart. Again, injections are continued as the needle is kept moving to reduce the risk of intravascular infusion (Fig. 1).

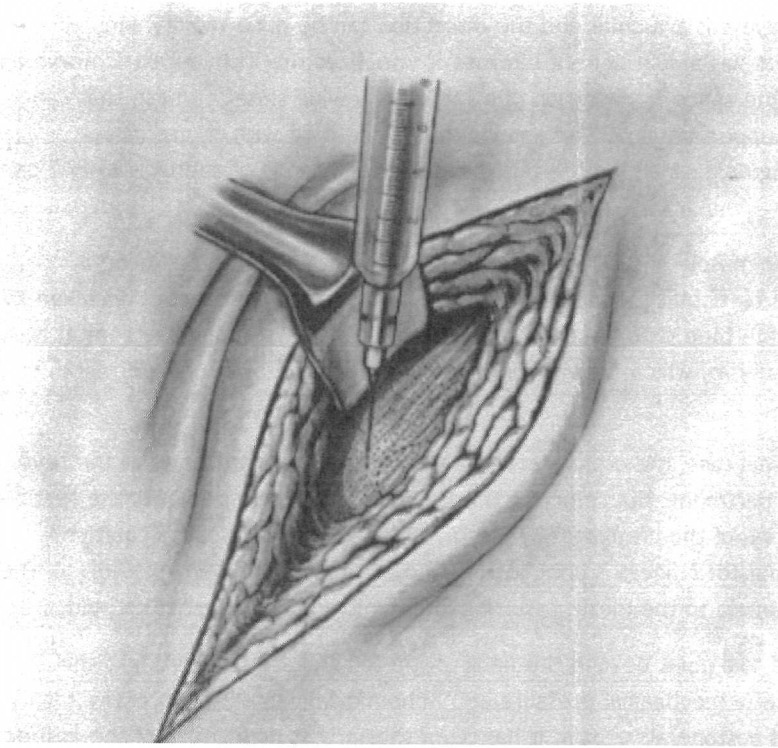


Fig. 2. Subaponeurotic injection through a small window at the lateral end of the incision.

Subaponeurotic Injection

Approximately 10 mL of the anesthetic mixture is injected immediately underneath the aponeurosis of the external oblique muscle through a window created in the subcutaneous fat at the lateral corner of the incision (Fig. 2). This injection floods the enclosed inguinal canal and anesthetizes all three major nerves in the

P.2111

region while the remaining subcutaneous fat is incised.

It also separates the external oblique aponeurosis from the underlying ilioinguinal nerve, reducing the likelihood of injuring the nerve when the external oblique aponeurosis is incised.

Occasionally it is necessary to infiltrate a few milliliters of the mixture at the level of the pubic tubercle, around the neck and inside the indirect hernia sac, to achieve complete local anesthesia.

Analgesic effect of the local anesthesia can be further prolonged by splashing 10 mL of the mixture into the inguinal canal before closure of the external oblique aponeurosis and in the subcutaneous space before skin closure.

Sedative drugs given by the surgeon—or preferably by an anesthetist as “conscious sedation” via infusion of rapid, short-acting, amnesic, and anxiolytic agents such as propofol—reduce the patient's anxiety. This also reduces the amount of local anesthetic agents required, particularly for bilateral inguinal hernia repair. Epidural anesthesia is preferred for repair of nonreducible inguinal hernias.

Technique of the Operation

A 5- to 6-cm skin incision, which starts from the pubic tubercle and extends laterally within the Langer line, gives an excellent exposure of the pubic tubercle and the internal ring. After skin incision, the external oblique aponeurosis is opened and its lower leaf is freed from the spermatic cord. The upper leaf of the external oblique is then freed from the underlying internal oblique muscle until the internal oblique aponeurosis is exposed.

The anatomic cleavage between these two layers is avascular and the dissection can be done rapidly and atraumatically. High separation of these layers has a dual benefit because it visualizes the iliohypogastric nerve and internal oblique aponeurosis and creates ample space for insertion of a sufficiently wide sheet of mesh that can overlap the internal oblique well above the upper margin of the inguinal floor. The cord with its cremaster covering is separated from the floor of the inguinal canal and the pubic bone for a distance of approximately 2 cm beyond the pubic tubercle.

The anatomic plane between the cremasteric muscle and attachment of rectus sheath to the pubic bone is avascular, so there is no risk of damaging the testicular blood flow. When lifting the cord, care should be taken to include the ilioinguinal nerve, the easily visible blue external spermatic vein (the blue line), and the genital nerve with the cord. This ensures that the genital nerve, which is always in juxtaposition to the external spermatic vessels, is preserved.

To explore the internal ring, for indirect hernia sacs, the cremasteric sheath is incised longitudinally at the level of the deep ring to access the cremasteric compartment. Not removing the cremasteric muscle prevents the testicle from hanging low and also prevents dysfunction of the cremasteric muscle, which may lead to dysejaculation. Complete stripping and resection of the cremasteric fibers is unnecessary and can result in direct exposure of the genital nerve, vas deferens, and paravasal nerves to the mesh, resulting in chronic groin and testicular pain.

Indirect hernial sacs are freed from the cord to a point beyond the neck of the sac and are inverted into the preperitoneal space without ligation. Because of mechanical pressure and ischemic changes, ligation of the highly innervated peritoneal sac is a major cause of postoperative pain. It has been shown that nonligation of the indirect hernia sac does not increase the chance of recurrence. To minimize the risk of postoperative ischemic orchitis, complete nonsliding scrotal hernia sacs are transected at the midpoint of the canal, leaving the distal section in place. However, the anterior wall of the distal sac is incised to prevent postoperative hydrocele formation.

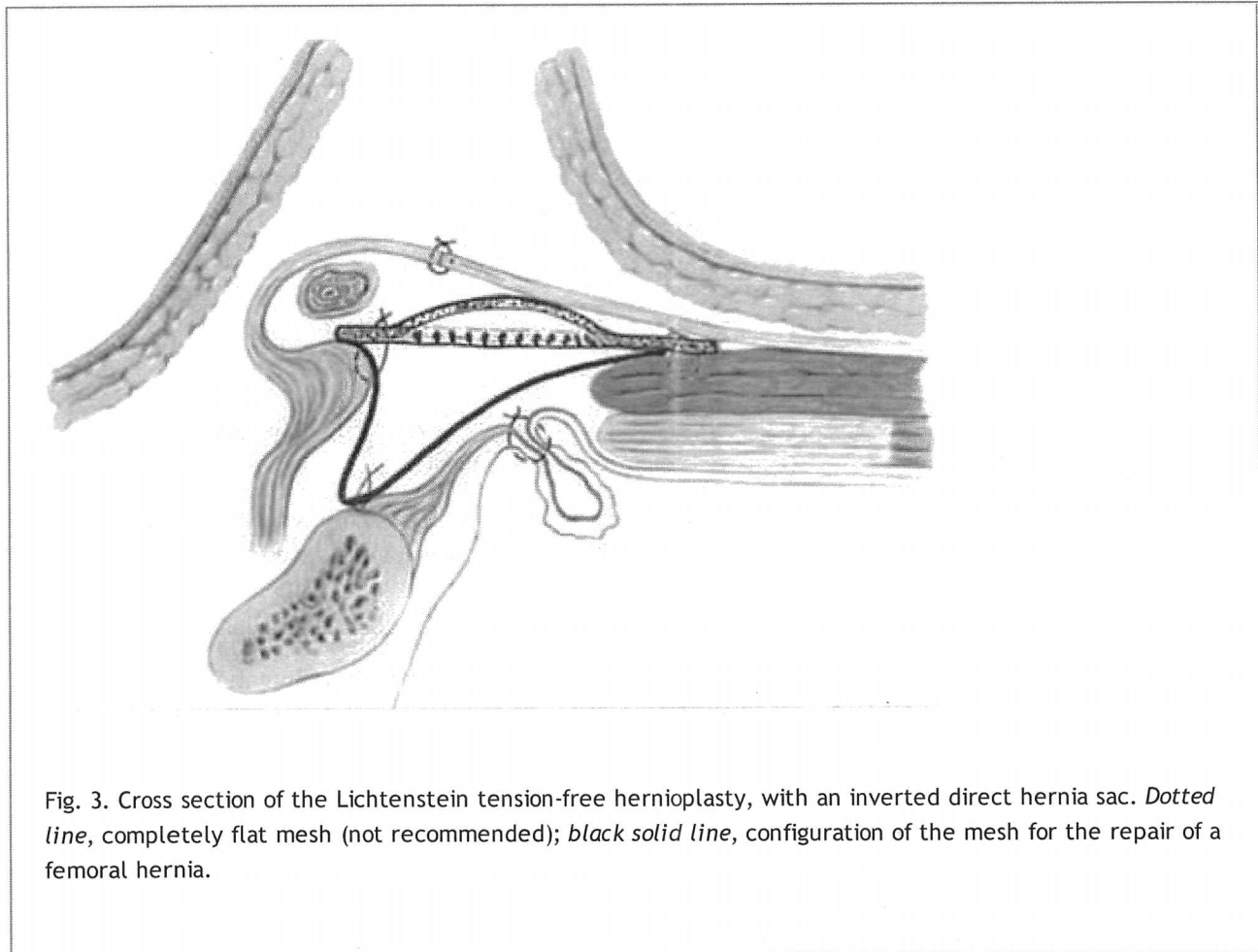


Fig. 3. Cross section of the Lichtenstein tension-free hernioplasty, with an inverted direct hernia sac. *Dotted line*, completely flat mesh (not recommended); *black solid line*, configuration of the mesh for the repair of a femoral hernia.

In the event of direct hernias, if large, the direct sacs are inverted with an absorbable suture (Fig. 3). A thorough exploration of the groin is necessary to rule out the coexisting intraparietal (interstitial), low-lying spigelian or femoral hernias. The femoral ring is routinely evaluated via the space of Bogros through a small opening in the canal floor. A sheet of 8 × 16 cm of mesh is used. We prefer monofilament macroporous polypropylene meshes because their monofilament structure does not perpetuate or harbor infection. The medial corner of the mesh is tailored to its standard shape, which resembles the tracing of a footprint, with a lower sharper angle to fit into the angle between the inguinal ligament and the rectus sheath and an upper wider angle to spread over the rectus sheath (Fig. 4). With the cord retracted upward, the sharper corner of the mesh is secured with a nonabsorbable monofilament suture to the insertion of the rectus sheath to the pubic bone overlapping the bone by 1 to 2 cm

P.2112

(Fig. 5). This is a crucial step in the repair because failure to cover this bone with the mesh can result in recurrence of the hernia. The periosteum of the bone is avoided. This suture is continued (as a continuous suture with up to four passages) to attach the lower edge of the patch to the inguinal ligament up to a point just lateral to the internal ring (Fig. 5). Suturing the mesh beyond this point is unnecessary and could injure the femoral nerve. If there is a concurrent femoral hernia, it can be fixed using my maneuver in which the mesh is also sutured to the Cooper's ligament 1 to 2 cm below its suture line with the inguinal ligament in order to close the femoral ring (Fig. 3, solid black line). Alternatively, the mesh can be tailored to have a triangular extension from its lower edge. The long side of the dropped-down triangle is sutured to the Cooper's ligament and the body of the mesh is sutured to the inguinal ligament along the solid line (Fig. 6).

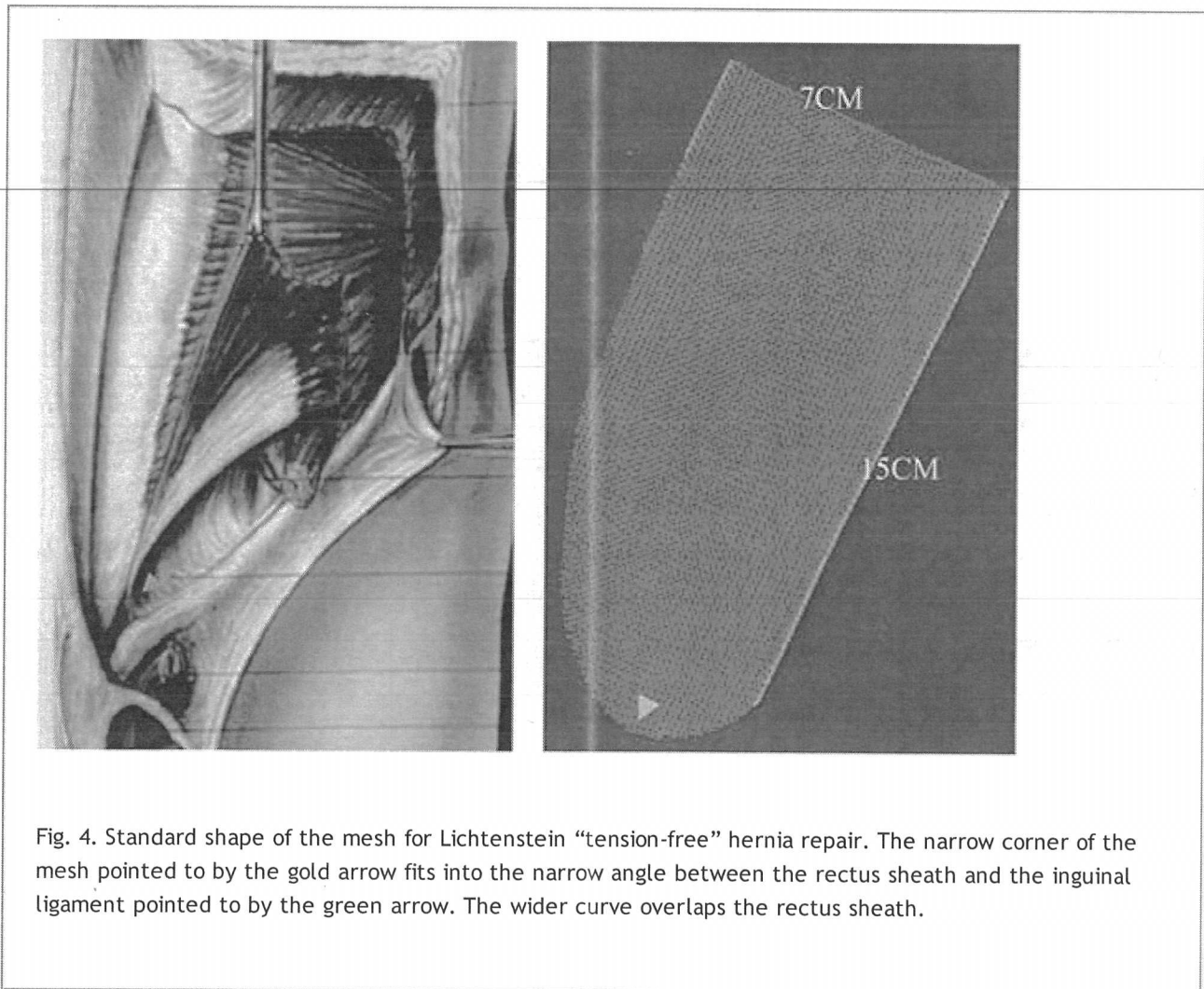


Fig. 4. Standard shape of the mesh for Lichtenstein “tension-free” hernia repair. The narrow corner of the mesh pointed to by the gold arrow fits into the narrow angle between the rectus sheath and the inguinal ligament pointed to by the green arrow. The wider curve overlaps the rectus sheath.

A slit is made at the lateral end of the mesh, creating two tails: a wide one (two-thirds) above and a narrower one (one-third) below. The wider upper tail is grasped with forceps and passed toward the head of the patient from underneath the spermatic cord; this positions the cord between the two tails of the mesh (Fig. 7).

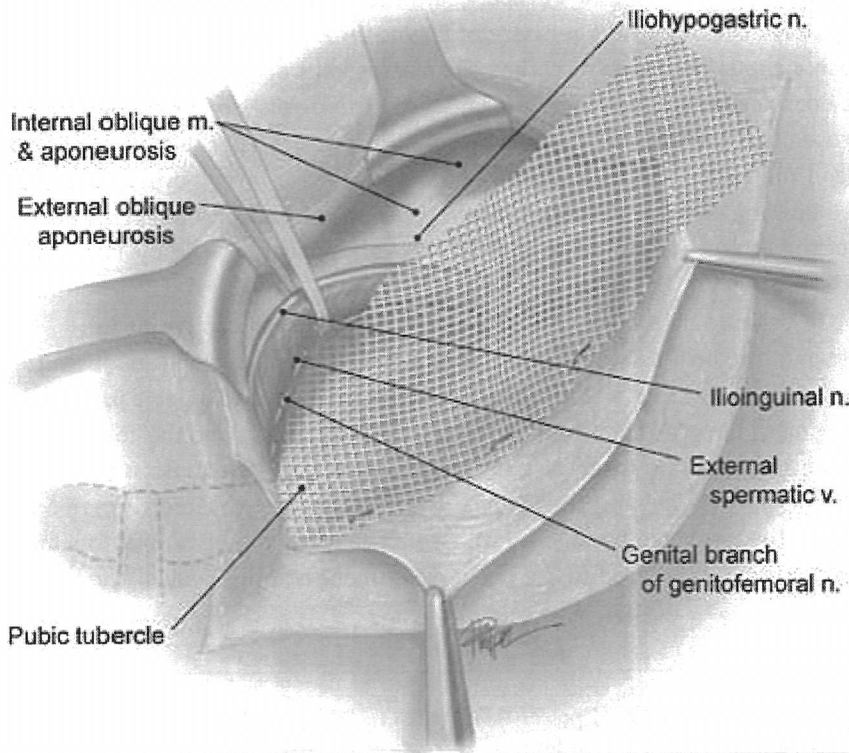


Fig. 5. Lower edge of the mesh is sutured to the inguinal ligament, overlapping the pubic bone by 2 cm.




Fig. 6. An alternative configuration of mesh for the repair of femoral hernia.

The wider upper tail is crossed and placed over the narrower one and held with a hemostat (Fig. 8). With the cord retracted downward and the upper leaf of the external oblique aponeurosis retracted upward, the upper edge of the patch is sutured in place with two interrupted absorbable

sutures, one to the rectus sheath and the other to the internal oblique aponeurosis, just lateral to the internal

ring (Fig. 8). Occasionally, the iliohypogastric nerve has an abnormal course and stands against the upper edge of the mesh. In those instances, a slit in the mesh will accommodate the nerve. If in doubt, the nerve can be resected with proximal-end ligation (to prevent traumatic neuroma formation) and implantation within the fibers of the internal oblique muscle to keep the stump of the nerve away from future scarring of the operative field. Suturing the upper edge of the mesh to the internal oblique muscle should be avoided to prevent injuring the intramuscular segment of the iliohypogastric nerve.

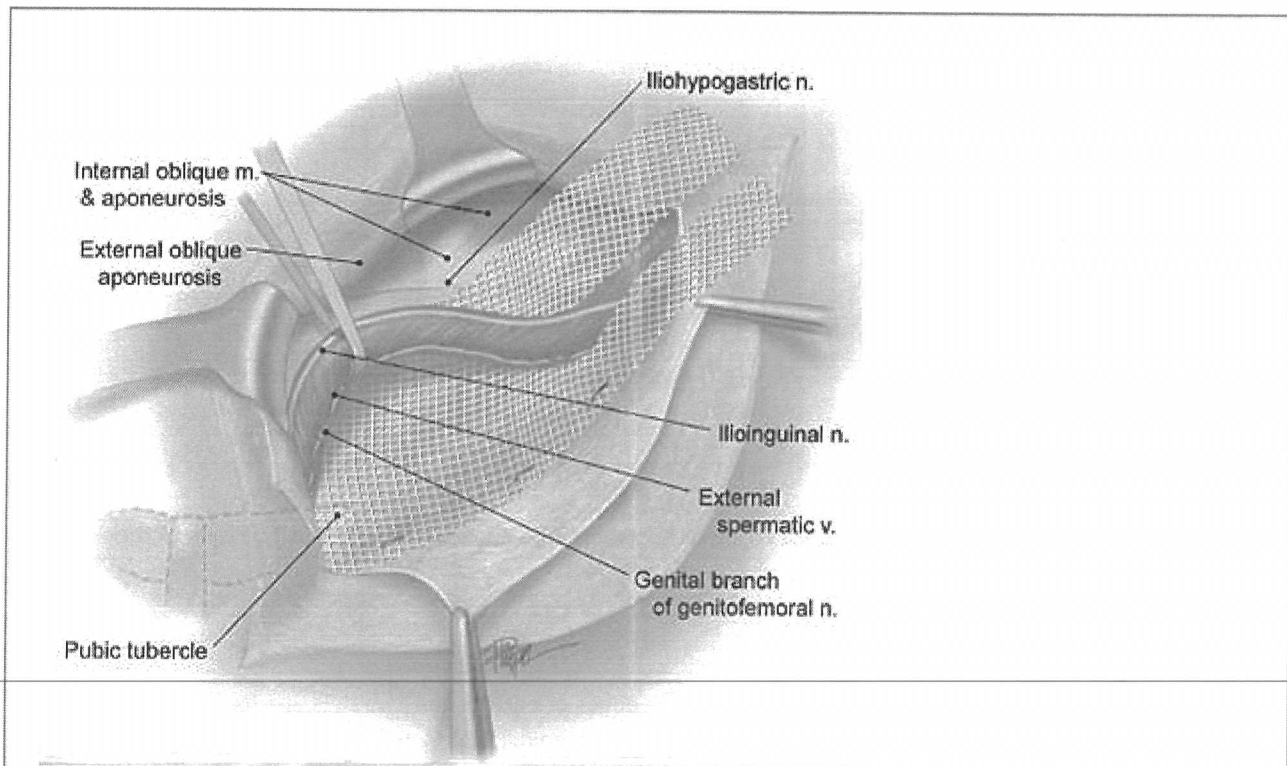


Fig. 7. A slit is made at the lateral end of the mesh, forming two tails, and the spermatic cord is placed in between the two tails.




Fig. 8. The upper edge of the mesh is sutured to the internal oblique aponeurosis and the two tails of the mesh are crossed.

Using a single nonabsorbable monofilament suture, the lower edges of each of the two tails are fixed to the inguinal ligament just lateral to the completion knot of the lower running suture, leaving adequate space for the passage of the spermatic cord. The excess patch on the lateral side is trimmed, leaving at least 5 cm of mesh beyond the internal ring. This is tucked underneath the external oblique aponeurosis, which is then closed over the cord with an absorbable suture (Fig. 9). Fixation of the tails of the mesh to the internal oblique muscle, lateral to the internal ring, is unnecessary and could result in entrapment of the ilioinguinal nerve with the fixation suture.

Technical Points for Minimizing Recurrence and Posthernia Repair Chronic Pain

There are five key elements of Lichtenstein tension-free hernioplasty based on (i) the physiodynamic characteristics of the abdominal wall and intra-abdominal pressure gradient, which rises from 8 cm of water, with the subject supine, to more than 80 cm of water on physical exertion, resulting in forward protrusion of the transversalis fascia; and (ii) shrinkage of the mesh *in vivo*, which, according to our laboratory and clinical studies (reported during the 1995 Annual Meeting of the American College of Surgeons), published in 1997 and confirmed by other investigators, is approximately 20%.

1. Use a large sheet of mesh (7 × 15 cm), with the standard shape of the tracing of a footprint (Fig. 4), extending approximately 2 cm medial to the pubic tubercle, 3 to 4 cm above the Hesselbach's triangle, and 5 to 6 cm lateral to the internal ring to account for mesh shrinkage.
2. Cross the tails of the mesh behind the spermatic cord to avoid recurrence lateral to the internal ring.
3. Secure the upper edge of the mesh to the rectus sheath and internal oblique aponeurosis with two interrupted sutures, and the lower edge of the mesh to the inguinal ligament with one continuous suture to prevent folding and movement of the mesh in the mobile area of the groin. Nonfixation or inadequate mesh fixation results in folding and wadding of the mesh (which, elsewhere, I have referred to as "meshoma"), which can cause chronic pain and recurrence of the hernia.

4. Keep the mesh in a slightly relaxed, tented up, or sagittate configuration to counteract the forward protrusion of the transversalis fascia when the patient stands up (Fig. 3). A mesh that is completely flat with no laxity or ripple (Fig. 3, dotted line) in a patient under sedation and in a recumbent position will be subject to tension when the patient strains or is in a standing position.
5. Visualize and protect the ilioinguinal, iliohypogastric, and genital nerves throughout the operation (Fig. 10). The iliohypogastric nerve can be identified easily while the external oblique

P.2114

aponeurosis is being separated from the internal oblique layer to make room for the mesh. Because of a natural anatomic cleavage, separation of these two layers from each other is easy, fast, and bloodless. The most vulnerable part of the iliohypogastric nerve is its intramuscular segment (Fig. 11), which runs along the lower edge of the internal oblique muscle (the so-called conjoint tendon). Passing a suture through the internal oblique muscle to approximate this layer to the inguinal ligament (during tissue approximation repairs) to a plug (during mesh plug repair) or to the upper edge of the mesh (during Lichtenstein repair) is liable to injure the intramuscular portion of the iliohypogastric nerve with the needle or entrap the nerve with the suture. The genital branch of the genitofemoral nerve is located under the cord, covered and protected from direct contact with mesh by the deep cremasteric fascia (Fig. 12). It is my opinion that the cremasteric muscle should not be removed, as such manipulation taught by some in the past exposes the genital nerve to perineural scarring and neuropathy due to direct contact with mesh. Furthermore, it exposes the vas and paravasal nerves to direct contact with mesh that can potentially lead to chronic orchialgia and infertility. The ilioinguinal nerve is located over the spermatic cord, covered and protected from the mesh by the investing fascia of the internal oblique muscle (Fig. 13). This protective fascia should not be damaged by removing the nerve from its natural bed. Dissecting the ilioinguinal nerve from the cord and placing it below the inguinal ligament (Fig. 14) (a commonly employed technique)

P.2115

destroys the protecting fascia of the nerve and increases the risk of chronic pain due to perineural scarring and direct contact of the nerve with mesh.




Fig. 9. The lower edges of both tails are sutured to the inguinal ligament leaving adequate space for the passage of spermatic cord and the lateral end of the mesh is tucked under the external oblique aponeurosis.

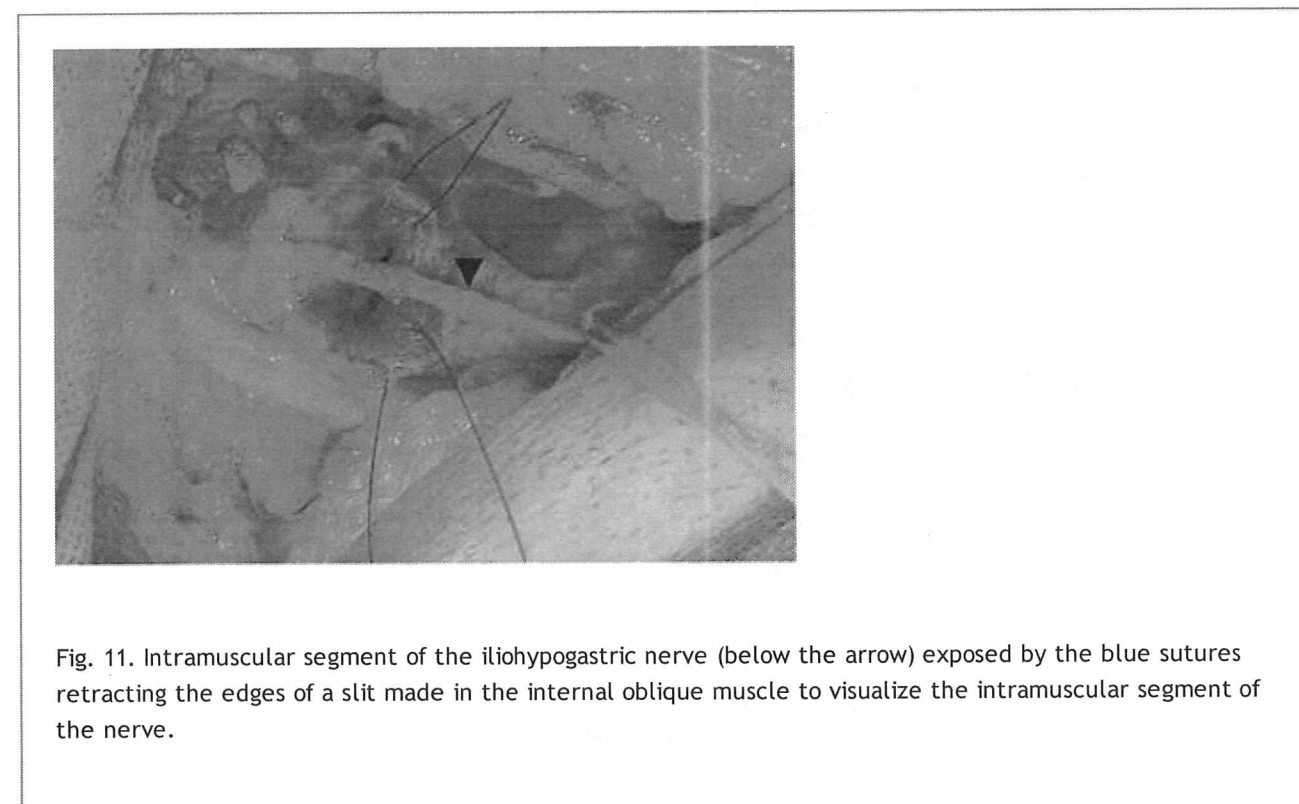
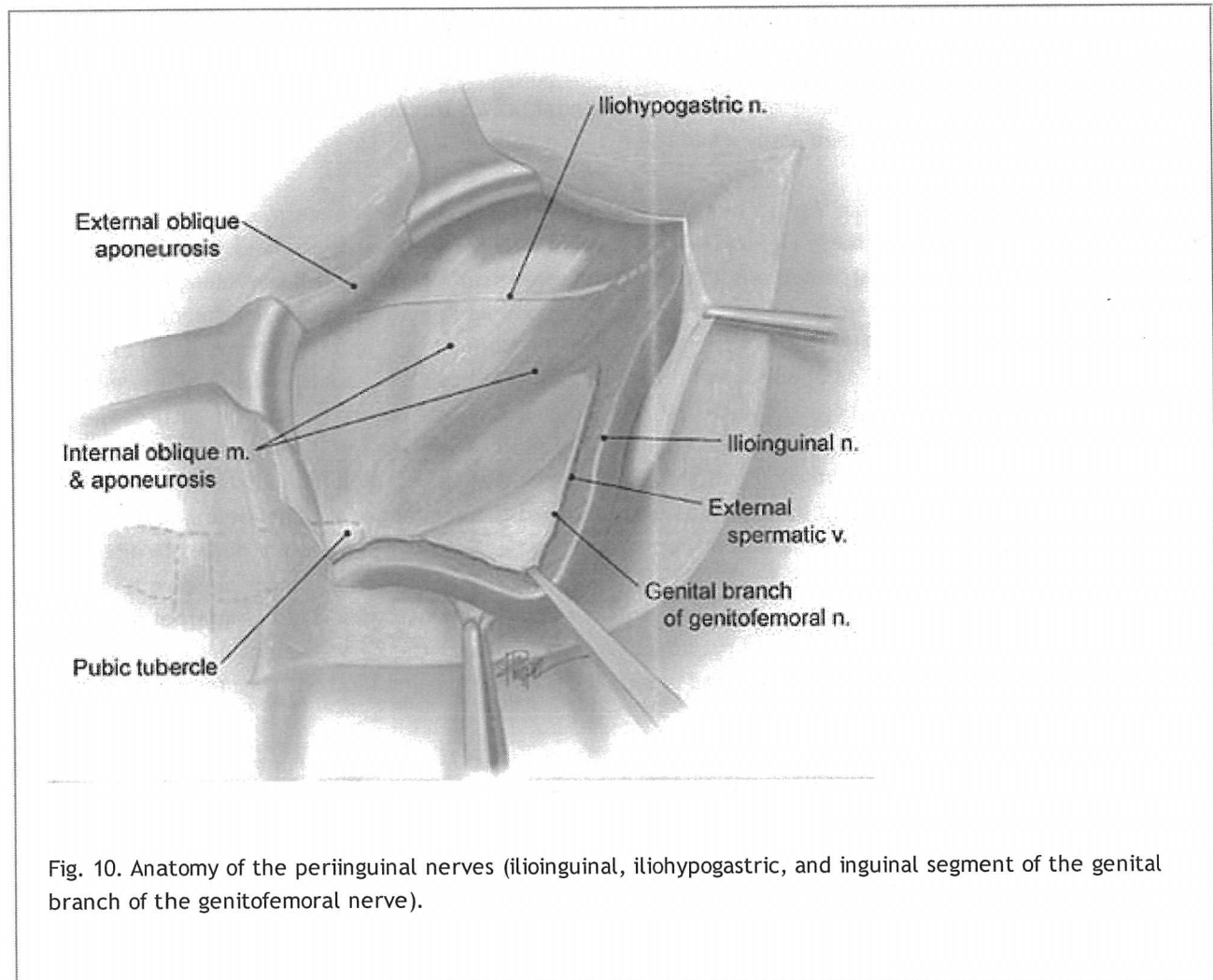
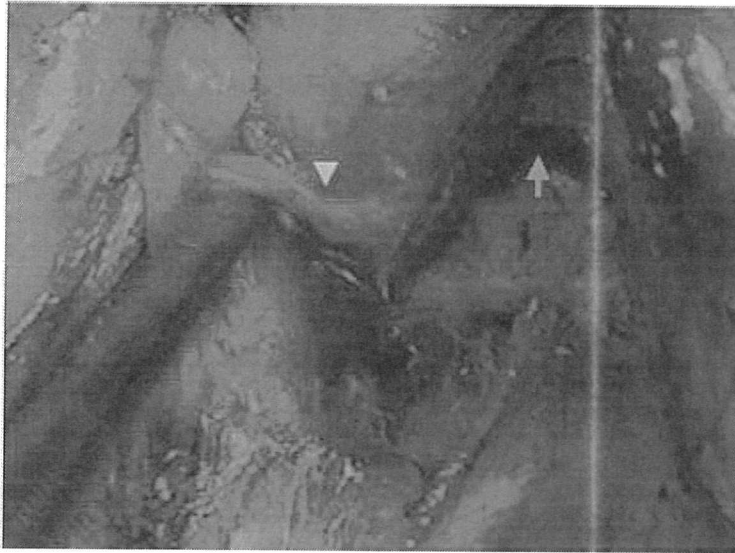



Fig. 12. Genital nerve (pointed to by gold arrow) next to the external spermatic vein (pointed to by green arrow).

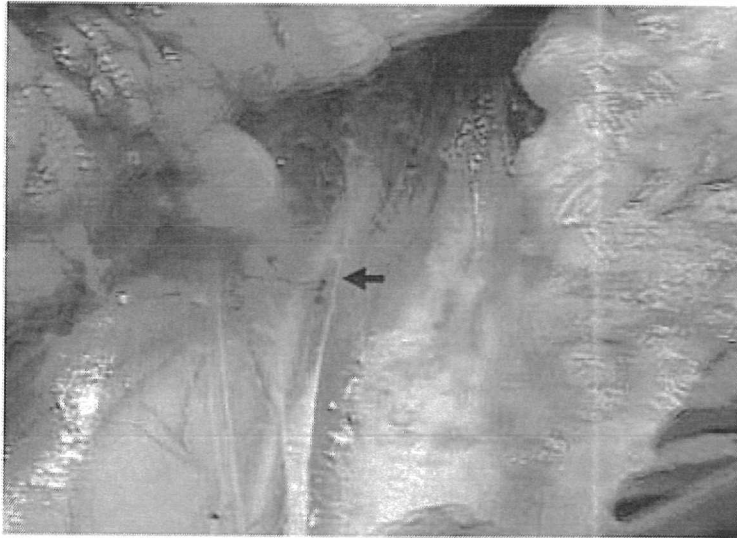


Fig. 13. Ilioinguinal; nerve is located over the cord, covered, and protected by the investing fascia of the internal oblique fascia (pointed to by the arrow).

Randomized Controlled Clinical Trials

Based on randomized controlled comparative studies (level A evidence), tension-free hernioplasty with mesh is superior to Bassini and Shouldice methods. Placement of mesh behind the transversalis fascia (properitoneal repair via open or laparoscopic repair), although a sound concept, requires extensive dissection in the highly complex properitoneal space, and exposes the preperitoneal nerves to direct contact with mesh and may lead to chronic

inguinodynia. In addition, it results in difficulty for future prostate surgery (see next section). According to a controlled randomized comparative trial from the University of Arkansas, recurrence rate of mesh implantation in front of the transversalis fascia, compared with behind the transversalis fascia, was the same; however, placement of mesh in front of the transversalis fascia was determined to be easier to perform and easier to learn and teach. In addition, according to the recent Veterans Affairs Cooperative Trial sponsored by the American Colleges of Surgeons comparing the Lichtenstein repair with laparoscopic approach (totally extraperitoneal preperitoneal and transabdominal preperitoneal), the Lichtenstein open tension-free repair was superior to the laparoscopic repair. Furthermore, the study demonstrated that laparoscopic approach resulted in a higher recurrence rate and was associated with operative mortality (an issue that is virtually unheard of with open hernia repair).

Conclusion

Since the introduction of the open tension-free hernioplasty in 1984, the operation has been evaluated and compared with other types of hernia repairs in several studies with regard to postoperative pain, postoperative time off work, complications, costs, and, not the least, recurrence rate. In fact, according to 2009 European Hernia Guidelines (prepared by 14 renowned European hernia experts from 14 European countries based on the review of 324 published clinical trials), "Lichtenstein technique, introduced in 1984, is currently the best evaluated and most popular of different open mesh techniques. It is reproducible with minimal morbidity; it can be performed in day care (under local anesthesia) and has low recurrence rates on the long-term." Furthermore, "Results of non-expert surgeons and even supervised residents using the Lichtenstein repair for primary inguinal hernias showed comparable excellent results to those of experts."

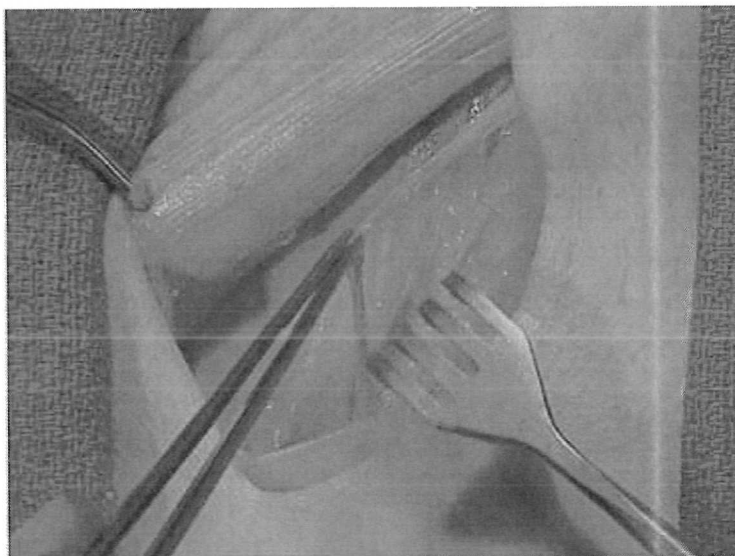


Fig. 14. Cadaver dissection showing separation of ilioinguinal nerve from the cord as was taught in the past.

P.2116

Suggested Readings

Amid PK. Classification of biomaterials and their related complications in abdominal wall hernia surgery. *Hernia* 1997;1:12.

Amid PK. Lichtenstein tension-free hernioplasty: its inception, evolution, and principles. *Hernia* 2004;8:1.

Amid PK. Causes, prevention, and surgical treatment of postherniorrhaphy neuropathic inguinodynia: triple neurectomy with proximal end implantation. *Hernia* 2004;8:343.

Amid PK. New understanding of the causes and surgical treatment of postherniorrhaphy inguinodynia and orchalgia. *J Am Coll Surg* 2007;205:381-5.

Amid PK. Radiologic images of meshoma: a new phenomenon after prosthetic repair of abdominal wall hernias. *Arch Surg* 2004;139:1297.

Amid PK, Shulman AG, Lichtenstein IL. Simultaneous repair of bilateral inguinal hernias under local anesthesia. *Ann Surg* 1996;223:249.

Kingsnorth AN, Bowley DMG, Porter C. A prospective study of 1000 hernias: results of the Plymouth Hernia Service. *Ann R Coll Surg Engl* 2003;85:18.

Neumayer L, Giobbie-Hurder A, Jonasson O, et al. Open mesh versus laparoscopic mesh repair of inguinal hernia. *N Engl J Med* 2004;250:1819.

Peiper C, Junge K, Klinge U, et al. Is there a risk of infertility after inguinal mesh repair? Experimental studies in the pig and rabbit. *Hernia* 2006;1:7-12.

Editor's Comment

The Lichtenstein or tension-free repair is generally thought of and spoken of as "the gold standard." I believe that this is unfortunate because of the insertion of mesh and because in many papers the nerve is not identified and, if it is, the fascial covering of the nerves may be breached, thus enabling nerve entrapment and inguinodynia. I have previously remarked that patients with chronic inguinodynia are miserable, and cannot perform many normal functions. I have always wondered why, given the misery that nerve entrapment generates, suture hernia repair has not made a comeback given the fact that its recurrence rate is probably no greater than 6% on average, although it has been as high as 9.3% (Rulli et al. *G Chir* 1998;19:285-9).

However, the difficulty of recurrence, while it requires an operation, as compared with inguinodynia, is nothing, as life is ruined in many patients with inguinodynia. A comparison therefore between the Lichtenstein repair or the "darn" procedure as described by Moloney (*Lancet* 1958;1:273-8), which to me represents a modified Shouldice procedure, is most welcome. Kucuk et al. (*Hernia* 2010;14[suppl]:357-60) compare the Lichtenstein repair with the Moloney darn procedure. In the study, 306 patients with inguinal hernia were divided into two groups: Group I included 176 patients on whom the darn procedure was performed; Group II included 130 patients on whom the Lichtenstein procedure was carried out. Four surgeons experienced in hernia performed the procedures. The darn procedure consisted of two apparently running monofilament polypropylene sutures between the inguinal ligament and the fascia of the internal oblique muscles. The results given in Table II of this paper indicate little difference between the two techniques. Wound infection rate was too high for a clean case: 5.1% for Group I and 5.4% for Group II. Follow-up at 2 years was not apparently different from 1 year and the recurrence rate was 4%.

One should remember that in Nuemayer's review of a Veteran's Affairs (VA) sponsored trial (Neumayer et al. *N Engl J Med* 2004;350:1819-57), the recurrence rate for a laparoscopic mesh repair was 10.1% while the recurrence rate of the open Lichtenstein repair was 4.1%. Because of this, Awad et al. (*Am J Surg* 2007;193:697-701) carried out an unfortunately noncurrent trial comparing the Lichtenstein Repair with the Prolene Hernia System mesh repair. Median follow-up was 17 months. The recurrence rate in the Prolene Hernia System repair was 0.6% versus 2.7% ($P = 0.04$) in the Lichtenstein tension-free repair.

There are two Eklund papers published at different times documenting the results of randomized multicenter trials with different laparoscopic repairs compared with the Lichtenstein repair. The first (Eklund et al., *Surg Endosc* 2007;21:634-40) is underpowered, with 73 patients in the transabdominal preperitoneal (TAPP) group and 74 patients in the Lichtenstein group. After 5 years, the recurrence rate was 19% in the TAPP group and 18% in the Lichtenstein group (ouch!). Recovery in the open group was delayed as at 3 weeks, 35% were still on sick leave in the open group as compared with 5% in the laparoscopic group ($P < 0.001$). Chronic postoperative pain was 25% in the Lichtenstein group and 15% in the TAPP group. Three surgeons from each hospital were responsible for 63% of all recurrences.

In the second Eklund paper (*Ann Surg* 2009;249:33-8), 1,512 patients were randomized to either Total Extraperitoneal (TEP) laparoscopic repairs or the Lichtenstein repair. The cumulative recurrence rate was 3.5% in the TEP group and only 1.2% in the Lichtenstein group ($P = 0.0008$). The exclusion of one surgeon who was responsible for 33% (7 of 21) of all recurrences in the TEP group lowered the cumulative recurrence to 2.4% in this group, which was not statistically significantly different from that in the Lichtenstein group, although elimination of a surgeon *post hoc* is not statistically significantly correct. The authors did not examine the huge difference of recurrence rate between the two Eklund papers (3.5% vs. 19%), and the same four surgeons were involved in both trials.

Ansaloni et al. (*Am J Surg* 2009;198:303-12) studied inguinal hernia repair with polypropylene mesh versus the Surgisis Inguinal Hernia Matrix. The authors recognize that the study is underpowered, with only 35 patients in a group. Nonetheless, after a 3-year follow-up, there was only one recurrence and that was in the polypropylene group. The biggest difference between the two groups in the study is a markedly decreased incidence of pain postoperatively in which there was 40% incidence of moderate pain on coughing in the polypropylene group versus a 3% incidence in the Surgisis group. Likewise, there was a 34% incidence of moderate pain on movement in the polypropylene group versus 0% in the Surgisis group. It may be that these differences are highly significant as surgisis may not cause an inflammatory reaction as does polypropylene.

In general, avoiding postoperative pain is a very important part of the Lichtenstein procedure and can be accomplished partially by not putting any sutures in the periosteum of the bone, especially the pubic tubercle. In addition, not breaching the fascia around the nerves is most important so as to not allow the nerves to become adherent to the polypropylene.

P.2117

Two other papers deal with complex or recurrent inguinal hernias. Beltrán and Cruces (*World J Surg* 2006;30:2281-7) used the qualitative and quantitative measurement instrument (QQMI) to evaluate 75 patients who underwent recurrent inguinal hernia repair and 287 patients who underwent primary repair in Chile. The results indicate that the Lichtenstein repair has a tendency to get better results in the primary repairs but, if surgeons do not have any experience with laparoscopic repairs, the Lichtenstein repair is appropriate.

Beitler et al. (*Hernia* 2009;13:61-6), writing from Rio De Janiero, have addressed a complicated pattern of the huge hernias and their approaches to what in the VA system we were prone to call "wheelbarrow hernias." Nonetheless, since they were willing to deal well with the complications of huge hydroceles; they were able to show good results.

J.E.F.